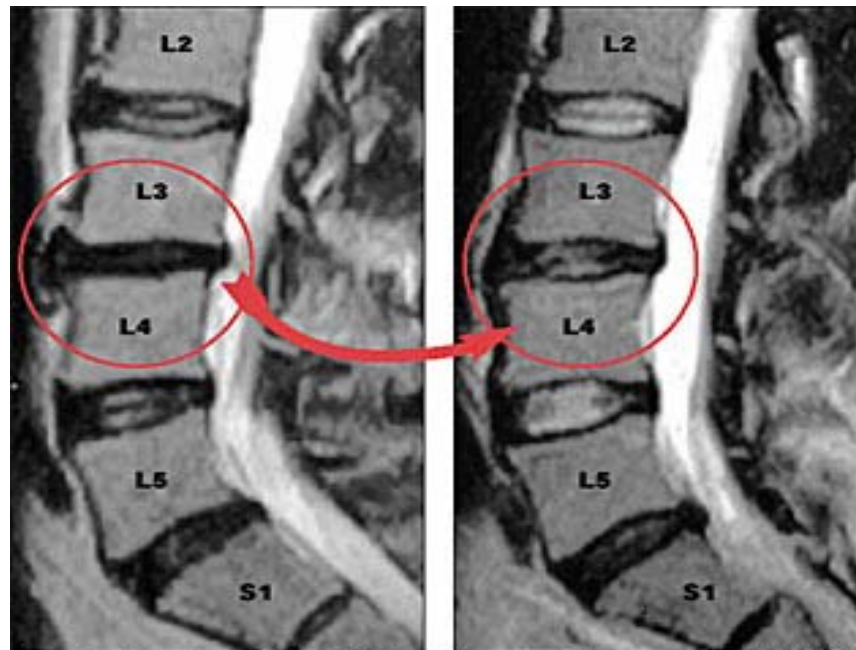


# IDD THERAPY<sup>®</sup> TREATMENT MRI STUDY



Pre Treatment MRI

Post Treatment MRI

- These are Pre and Post MRI studies of a 52-year old man.
- The patient had been injured for 1-½ years and had undergone 9 months of Physical Therapy.
- Disc herniations were found at both L3-L4 and L5-S1.
- After only 11 sessions of a typical 20-session protocol on the Accu-SPINA™ System, the patient was much improved.
- Disc L3-L4 had an improved hydration status, the herniation interior and posterior were diminished and the disc height improved.
- The normal disc above and below demonstrated an increase in disc height and improved hydration.